

## RAPID COMMUNICATION

# Identification and Complete Genome of Seneca Valley Virus in Vesicular Fluid and Sera of Pigs Affected with Idiopathic Vesicular Disease, Brazil

F. A. Vannucci<sup>1</sup>, D. C. L. Linhares<sup>2</sup>, D. E. S. N. Barcellos<sup>3</sup>, H. C. Lam<sup>1</sup>, J. Collins<sup>1</sup> and D. Marthaler<sup>1</sup>

<sup>1</sup> University of Minnesota Veterinary Diagnostic Laboratory, College of Veterinary Medicine, University of Minnesota, St. Paul, MN, USA

<sup>2</sup> Agroceres PIC, Rio Claro, Brazil

<sup>3</sup> Setor de Suínos, Faculdade de Veterinária, Universidade Federal do Rio Grande do Sul, Porto Alegre, Brazil

**Keywords:**

Seneca Valley virus; complete genome; vesicular disease; Brazil

**Correspondence:**

F. A. Vannucci. University of Minnesota Veterinary Diagnostic Laboratory, College of Veterinary Medicine, University of Minnesota, 1333 Gortner Avenue, St. Paul, MN 55108-1098, USA. Tel.: +1 612 624 0391; Fax: +1 612 624 8707; E-mail: vannu008@umn.edu

Received for publication June 29, 2015

doi:10.1111/tbed.12410

**Summary**

Numerous, ongoing outbreaks in Brazilian swine herds have been characterized by vesicular lesions in sows and acute losses of neonatal piglets. The complete genome of Seneca Valley virus (SVV) was identified in vesicular fluid and sera of sows, providing evidence of association between SVV and vesicular disease and viraemia in affected animals.

**Introduction**

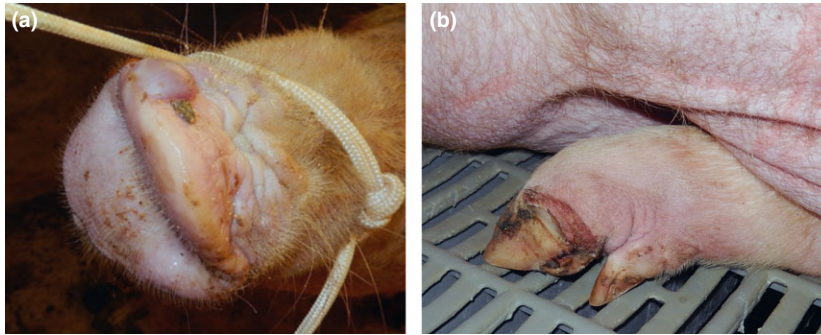
Seneca Valley virus (SVV) belongs to the family *Picornaviridae*, species *Senecavirus A* in the genus *Senecavirus*, and is a most closely related member of the genus *Cardiovirus* (Knowles et al., 2012; Adams et al., 2015). The virus was first identified as a contaminant in PER.C6 cell cultures and subsequently has been isolated from pigs in the United States and Canada (Hales et al., 2008; Knowles and Hallenbeck, 2005; Pasma et al., 2008). The genetic analysis of two genomic regions (3' end and VP1-coding region) in seven SVV isolates revealed a common ancestor and suggested a recent introduction of this virus in the US pig population (Knowles et al., 2006).

In 2007, pigs displayed clinical signs resembling vesicular disease at a harvest facility in Minnesota, USA, where the animals arrived from Canada (Pasma et al., 2008). Approximately 80% of the pigs on the transport trailer were lame (Pasma et al., 2008). These animals tested negative by PCR for foot-and-mouth disease, swine vesicular disease, vesicular stomatitis and vesicular exanthema, but

they were positive for SVV. The disorder was reported as idiopathic vesicular disease. This report describes the identification and the complete SVV genome in vesicular fluid and sera of pigs affected with idiopathic vesicular disease in Brazil.

**Materials and Methods**

In November 2014, several acute outbreaks have been reported in Brazil describing three main characteristics: (i) the presence of vesicles and coalescing erosions on the snouts and coronary bands of sows (Fig. 1), (ii) acute loss of neonatal piglets (30–70%) in the first four days of age and (iii) self-limiting outbreaks lasting approximately 1–2 weeks. Occasionally, the vesicles and erosions on the coronary bands were also observed in the convalescing piglets. In many cases, the reports are initially limited to acute significant losses of newborn piglets likely due to the short-lived vesicular lesions. In addition, these losses were sometimes associated with lethargy, neurological signs and/or diarrhoea in neonatal piglets. No significant changes on



**Fig. 1.** Vesicular disease associated with the presence of Seneca Valley virus. (a) Intact vesicle on the snout an affected sow. (b) Erosive lesion bordering the coronary band in the left rear hoof of an affected sow.

body temperature or farrowing rate of affected sow herds were observed.

In February of 2015, the University of Minnesota Veterinary Diagnostic Laboratory (UMVDL) received two cases from affected sows in Minas Gerais and Goiás, Brazil. The first case contained a sample of vesicular fluid and two sera, while the second case contained a single vial of vesicular fluid. After testing negative by PCR for foot-and-mouth disease virus, swine vesicular disease virus, vesicular stomatitis virus and vesicular exanthema virus in a Brazilian official veterinary laboratory, the samples were submitted for unknown pathogen discovery through next-generation sequencing.

The package containing the samples was opened at a biosecurity level 3 facility to limit the potential introduction of foreign animal diseases in the United States. The appropriate volume of sample was placed into lysis buffer following the United States Department of Agriculture (USDA) Standard Operation Procedure (SOP) entitled, 'Extraction of Total RNA Using a MagMax-96 Total RNA Isolation Kit for the Detection of Classical Swine Fever and Foot-and-Mouth Diseases Viruses' (SOP-PVS-0004.01). The RNA was tested for foot-and-mouth disease virus using USDA SOP entitled, 'Preparation, Performance and Interpretation of a Real-Time PCR Assay for Foot-and-Mouth Disease Virus on the Applied Biosystems 7500 Real-time PCR System' (Life Technologies, Grand Island, NY, USA). The RNA was tested for vesicular stomatitis, swine vesicular disease and vesicular exanthema of swine (VES) using the QIAGEN OneStep RT-PCR kit (QIAGEN, Hilden, Germany), using the following cycling conditions: 50°C for 30 min and 95°C for 15 min for the RT reaction, followed by 40 cycles of amplification at 95°C for 30 s, 50°C for 30 s and 72°C for 1 min, with a final extension at 72°C for 10 min.

The RNA was submitted to the University of Minnesota Genomics Center for library preparation with the Illumina TruSeq RNA Sample Prep Kit (Illumina Inc., San Diego, CA, USA). Multiple samples were indexed into a single MiSeq 250 Nano run (Illumina Inc.). Raw pair-end reads

generated from the Illumina MiSeq machine (Illumina Inc.) were used in a genome assembly pipeline for viral genome construction. The assembly was performed on a 64-bit Linux (kernel 2.6.31) OS, multiprocessor, multicore 2.66-GHz CPU workstation with 128 GB memory. Raw reads were trimmed using Trimmomatic (version 0.32; The Usadel Lab, Jülich, Germany) to remove adapter sequences with a sliding window of 4 and quality value cut-off of 16, and duplicate read-pairs were removed. Bowtie2 (version 2.2.2; Johns Hopkins University, Baltimore, MD, USA) mapping software was used as a filtering tool to remove reads that mapped to swine genome and other bacterial organism genomes (*Bradyrhizobium*, *E. coli*, *Pseudomonas*, *Salmonella* phage, *Streptococcus*, etc.). The pair-end reads that remained after the filtering procedure were collected for assembly using an open-source *de novo* assembler (Tritt et al., 2012). The assembly process included insertion size estimation, contig generation and scaffolding. NCBI\_Blast+ (version 2.2.28; National Center for Biotechnology Information, Bethesda, MD, USA) BLASTn tool was used to identify scaffolds produced by the *de novo* assembly workflow against the nucleotide collection (nr/nt) database. The two complete genomes generated from this study and the available SVV genomes from GenBank were aligned using MUSCLE (<http://drive5.com/muscle/>), and a maximum-likelihood phylogenetic tree was constructed with 1000 bootstraps. After the identification of SVV by unknown pathogen discovery, additional samples were tested by SVV RT-PCR as previously described.

## Results and Discussion

The initial diagnostic investigation also revealed inconsistent presence of lesions and isolation of bacteria commonly found in healthy pigs or associated with secondary infections, including *Clostridium perfringens*, *Clostridium difficile*, *Streptococcus suis* and *Actinobacillus suis*. The histological lesions observed in the skin from the vesicular lesions revealed hyperkeratosis, intra- and inter-cellular oedema of keratinocytes predominantly in the stratum

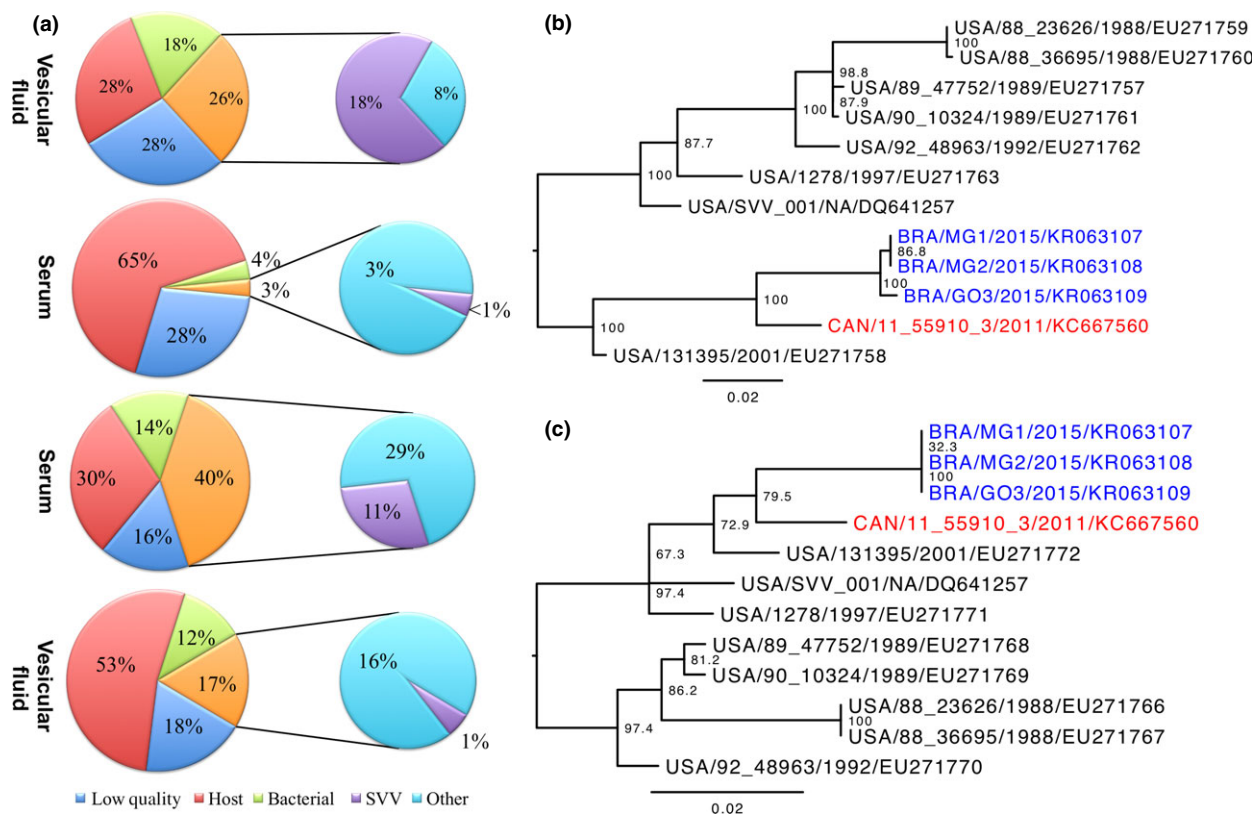
basale and spinosum and acantholytic degeneration of basal keratinocytes. Fibrinosuppurative dermatitis with the presence of intralesional bacteria was also observed and interpreted as secondary lesions likely due to opportunistic bacterial colonization (Singh et al., 2012). A comprehensive diagnostic investigation ruled out other potential aetiologies including parvovirus (Kresse et al., 1985), enterovirus group III (Knowles, 1988), mycotoxins (Osweiler and Ensley, 2012), chemical/thermal burns and photodermatitis caused by phototoxic compound present in parsnips, celery and carrots contaminated with the fungus *Sclerotinia sclerotiorum* (Montgomery et al., 1987).

After removing host, bacterial, and low-quality reads, 3–40% of the total reads were available for *de novo* assembly for each sample (Fig. 2a). Of the assembled reads, <1–11% matched the SVV genome, while the remaining reads mapped to bacterial genomes that were not removed initially or reads that had unknown hits when blasting against the NCBI database. No other viral reads were identified in

the samples. Complete genomes were constructed from the first case, samples one and three (MG1 and MG2), and the second case (GO3).

The SVV complete genome sequences shared a 99.5% nucleotide identity while sharing a 94.2–96.5% nucleotide identity to two complete SVV genomes in GenBank. Two phylogenetic trees were constructed from the VP1 region (2550–3486 nucleotides) and the partial 3Dpol and complete 3'UTR (6834–7284 nucleotides), and both trees illustrate that the Brazilian SVV strains share a common ancestor with the Canadian strain than with the US strains. After SVV had been discovered by next-generation sequencing, cases from Rio Grande do Sul, Brazil, were received and tested positive for SVV by RT-PCR.

Comprehensive clinical and epidemiological characterization of vesicular disease outbreaks is critical due to resemblance to foot-and-mouth disease, swine vesicular disease, vesicular stomatitis and vesicular exanthema of swine. While previous reports suggest the association of



**Fig. 2.** Percentages of next-generation sequencing reads and phylogenetic trees. (a) Pie charts representing the percentage of reads for each sample (case 1, samples 1, 2 and 3, and case 2, sample 2 in descending order). The percentage of low-quality reads (including duplicated reads) is represented in blue, the percentage of host reads is represented in red, the percentage of bacterial reads is represented in green, and the percentage of reads for *de novo* assembly is represented in orange. A sub-pie chart of the assembly reads illustrates the percentage of Seneca Valley virus reads (purple) and percentage of other reads (aqua), which includes bacterial reads and reads that were identified as unknown by BLASTn searching against the NCBI nr/nt database. (b) Phylogenetic tree of the partial VP1 gene. (c) Phylogenetic tree of the partial 3Dpol and complete 3'UTR regions. Strains coloured blue are from this study, strains coloured black are from the United States, and the strain coloured red is from Canada.

SVV with vesicular disease in pigs, this report provides additional evidence of this association strengthened by the significant presence of SVV RNA in the sera of affected sows (Pasma et al., 2008; Singh et al., 2012). Nevertheless, SVV has also shown low virulence or non-virulence in pigs from North America (Hales et al., 2008; Pasma et al., 2008). In a single case report, SVV was identified by PCR in vesicular lesions in a boar, and the animal was euthanized due to the progression of the disease, including deep ulcers in the nasal and oral cavity, anorexia, lethargy and lameness (Singh et al., 2012). The virulence of the Brazilian cases may be potentially due to the exposure of a naïve pig population. In the United States, neutralizing antibodies to SVV were reported in pigs, cows and mice (Knowles et al., 2006). However, studies were unable to experimentally reproduce illness in pigs using two SVV isolates (Knowles et al., 2006; Yang et al., 2012).

The present study demonstrated significant presence of SVV RNA in the swine serum samples of pigs exhibiting vesicular and erosive lesions. Although our report has not comprised sequencing data from non-clinically affected animals, serological surveillances using viral metagenomic technologies have not found SVV in porcine sera (Masembe et al., 2012; Blomström et al., 2012; Han et al., 2013). These surveillances have described numerous other viruses in porcine tissues and sera, including African swine fever virus, porcine endogenous retroviruses, arbovirus, Torque teno virus, porcine parvovirus, porcine endogenous retrovirus, GB hepatitis C-like virus, Sclerotinia hypovirulence-associated-like virus, classical swine fever virus, porcine circovirus type 2, porcine bocavirus and human adenovirus type 6. From our knowledge, SVV has yet to be reported in porcine sera and from Latin America. Swine populations in different geographical regions may have their own diversity of viruses driving by the environment and virus exposures. As a result, future studies are warranted to characterize the background of viruses present in the serum of the Brazilian swine herds.

An intriguing feature reported in affected herds in Brazil has been the sudden death in neonatal piglets, recently named epidemic transient neonatal losses (ETNL) syndrome (D. C. L. Linhares, personal communication). To the best of our knowledge, SVV has not been associated with neonatal losses. During these outbreaks in Brazil, systemic and enteric bacterial infections have been inconsistently reported in neonatal piglets. Seneca Valley virus was identified by PCR from ETNL-affected piglets in the following tissues: lung, heart, liver, spleen, kidney and intestine. Additionally, erosive lesions on the coronary bands of convalescent piglets have been occasionally observed and might indicate the involvement SVV.

However, further investigations are needed to confirm the aetiology of the ETNL.

The significant presence of SVV sequences in the sera revealed potential viraemia in affected animals. Although there are various outbreaks in Brazil with similar clinical and epidemiological features described here, a consistent identification and distribution of SVV is crucial for a more comprehensive characterization of this virus as a causative agent of vesicular disease.

## References

- Adams, M. J., E. J. Lefkowitz, A. M. Q. King, D. H. Bamford, M. Breitbart, A. J. Davison, S. A. Ghabrial, A. E. Gorbalenya, N. J. Knowles, P. Krell, R. Lavigne, D. Prangishvili, H. Sanfaçon, S. G. Siddell, P. Simmonds, and E. B. Carstens, 2015: Ratification vote on taxonomic proposals to the International Committee on Taxonomy of Viruses (2015). *Arch. Virol.* 160, 1837–1850.
- Blomström, A. L., K. Ståhl, C. Masembe, E. Okoth, A. R. Okurut, P. Atmnedi, S. Kemp, R. Bishop, S. Belák, and M. Berg, 2012: Viral metagenomic analysis of bushpigs (*Potamochoerus larvatus*) in Uganda identifies novel variants of Porcine parvovirus 4 and Torque teno sus virus 1 and 2. *Virol. J.* 9, 192.
- Hales, L. M., N. J. Knowles, P. S. Reddy, L. Xu, C. Hay, and P. L. Hallenbeck, 2008: Complete genome sequence analysis of Seneca Valley virus-001, a novel oncolytic picornavirus. *J. Gen. Virol.* 89, 265–275.
- Han, W., Y. Luo, B. Zhao, Y. Sun, S. Li, and H. Qiu, 2013: Metagenomics-based detection of swine viruses. *Wei Sheng Wu Xue Bao* 53, 197–203.
- Knowles, N. J., 1988: The association of group III porcine enteroviruses with epithelial tissue. *Vet. Rec.* 122, 441–442.
- Knowles, N. J., and P. L. Hallenbeck, 2005: A new picornavirus is most closely related to cardioviruses. *Abstract of the EUROPIC 2005 – 13th meeting of the European Study Group on the Molecular Biology of Picornaviruses; Lunteren, the Netherlands; 23–29.*
- Knowles, N. J., L. M. Hales, B. H. Jones, J. G. Landgraf, J. A. House, K. L. Skele, K. D. Burroughs, and P. L. Hallenbeck, 2006: Epidemiology of Seneca Valley virus: identification and characterization of isolates from pigs in the United States. In: *Abstracts of the Northern Lights EUROPIC 2006 – XIV Meeting of the European Study Group on the Molecular Biology of Picornaviruses, Saariselkä, Inari, Finland; November 26th – December 1st.* Abstract G2.
- Knowles, N. J., T. Hovi, T. Hyypiä, A. M. Q. King, A. M. Lindberg, M. A. Pallansch, A. C. Palmenberg, P. Simmonds, T. Skern, G. Stanway, T. Yamashita, and R. Zell, 2012: Picornaviridae. In: King, A. M. Q., M. J. Adams, E. B. Carstens, and E. J. Lefkowitz (eds), *Virus Taxonomy: Classification and Nomenclature of Viruses: Ninth Report of the International Committee on Taxonomy of Viruses*, pp. 855–880. Elsevier, San Diego.

- Kresse, J. I., W. D. Taylor, W. W. Stewart, and K. A. Eernisee, 1985: Parvovirus infection in pigs with necrotic and vesicle-like lesions. *Vet. Microbiol.* 10, 525–531.
- Masembe, C., G. Michuki, M. Onyango, C. Rumberia, M. Norling, R. P. Bishop, A. Djikeng, S. J. Kemp, A. Orth, R. A. Skilton, K. Ståhl, and A. Fischer, 2012: Viral metagenomics demonstrates that domestic pigs are a potential reservoir for Ndumu virus. *Virology* 9, 218.
- Montgomery, J. F., R. E. Oliver, and W. S. H. Poole, 1987: A vesiculo-bullous disease in pigs resembling foot and mouth disease I. Field cases. *N. Z. Vet. J.* 35, 21–26.
- Osweiler, G. D., and S. M. Ensley, 2012: Mycotoxins. In: Zimmerman, J. J., L. A. Karriker, A. Ramirez, K. J. Schwartz, and G. W. Stevenson (eds), *Diseases of Swine*, 10th edn, pp. 915–929. Blackwell Publishing, Ames.
- Pasma, T., S. Davidson, and S. L. Shaw, 2008: Idiopathic vesicular disease in swine in Manitoba. *Can. Vet. J.* 49, 84–85.
- Singh, K., S. Corner, S. G. Clark, G. Scherba, and R. Fredrickson, 2012: Seneca Valley virus and vesicular lesions in a pig with idiopathic vesicular disease. *J. Vet. Sci. Technol.* 3, 123.
- Tritt, A., J. A. Eisen, M. T. Facciotti, and A. E. Darling, 2012: An integrated pipeline for de novo assembly of microbial genomes. *PLoS One* 7, e42304.
- Yang, M., R. van Bruggen, and W. Xu, 2012: Generation and diagnostic application of monoclonal antibodies against Seneca Valley virus. *J. Vet. Diagn. Invest.* 24, 42–50.